



Original Article

ESTRO consensus guideline for target volume delineation in the setting of postmastectomy radiation therapy after implant-based immediate reconstruction for early stage breast cancer



Orit Kaidar-Person^{a,*}, Birgitte Vrou Offeresen^{b,1}, Sandra Hol^c, Meritxell Arenas^d, Cynthia Aristei^e, Celine Bourcier^f, Maria Joao Cardoso^g, Boon Chua^h, Charlotte E. Colesⁱ, Tine Engberg Damsgaard^j, Dorota Gabrys^k, Reshma Jaggi^l, Rachel Jimenez^m, Anna M. Kirbyⁿ, Carine Kirkove^o, Youlia Kirova^p, Vassilis Kouloulis^q, Tanja Marinko^r, Icro Meattini^s, Ingvil Mjaaland^t, Gustavo Nader Marta^{u,v}, Petra Witt Nystrom^w, Elzbieta Senkus^x, Tanja Skyttä^y, Tove F. Tvedskov^z, Karolien Verhoeven^{aa}, Philip Poortmans^{ab}

^a Oncology Institute, Radiation Oncology Unit, Rambam Medical Center, Haifa, Israel; ^b Department of Experimental Clinical Oncology, Danish Center for Particle Therapy, Department of Oncology, Aarhus University Hospital, Denmark; ^c Department of Radiation Oncology, Institute Verbeeten, Tilburg, the Netherlands; ^d Department of Radiation Oncology, Hospital Universitari Sant Joan de Reus, University Rovira i Virgili, Spain; ^e Radiation Oncology Section, Department of Surgical and Biomedical Science, University of Perugia and Perugia General Hospital, Italy; ^f Department of Radiation Oncology, ICM – Val d'Aurelle, INSERM U1194, ICM; Montpellier University, Montpellier, France; ^g Breast Unit, Champalimaud Foundation, and Nova Medical School, Lisbon, Portugal; ^h Faculty of Medicine, The University of New South Wales, UNSW Sydney, NSW, Australia; ⁱ Cambridge University, Department of Oncology, United Kingdom; ^j Department of Plastic and Breast Surgery, Aarhus University Hospital, Denmark; ^k Department of Radiation Oncology, Maria Skłodowska Curie Memorial Cancer Centre, Gliwice, Poland; ^l Department of Radiation Oncology, University of Michigan, Ann Arbor, USA; ^m Department of Radiation Oncology, Massachusetts General Hospital, Boston, USA; ⁿ Department of Radiotherapy, Royal Marsden NHS Foundation Trust and Institute of Cancer Research, Sutton, UK; ^o Department of Radiation Oncology, University Hospital St-Luc, Brussels, Belgium; ^p Department of Radiation Oncology, Institut Curie, Paris, France; ^q National and Kapodistrian University of Athens, Medical School, 2nd Dpt of Radiology, Radiotherapy Unit, Athens, Greece; ^r Department of Radiation Oncology, Institute of Oncology Ljubljana, Slovenia; ^s Department of Biomedical, Experimental, and Clinical Sciences, University of Florence, Italy, Radiation Oncology Unit – Oncology Department, Azienda Ospedaliero-Universitaria Careggi, Florence, Italy; ^t Department of Oncology & Radiotherapy, Stavanger University Hospital, Norway; ^u Department of Radiation Oncology, Hospital Sirio-Libanês, São Paulo, Brazil; ^v Department of Radiology and Oncology, Division of Radiation Oncology, Instituto do Câncer do Estado de São Paulo (ICESP), Faculdade de Medicina da Universidade de São Paulo, Brazil; ^w The Skandion Clinic, Uppsala, Sweden and Danish Center for Particle Therapy, Aarhus, Denmark; ^x Department of Oncology & Radiotherapy, Medical University of Gdańsk, Poland; ^y Department of Oncology, Tampere University Hospital, Finland; ^z Dept. of Breast Surgery, Herlev Hospital, Copenhagen, Denmark; ^{aa} GROW School for Oncology and Developmental Biology, Department of Radiation Oncology, Maastricht University Medical Centre, Netherlands; ^{ab} Department of Radiation Oncology, Institut Curie, and Paris Sciences & Lettres University, Paris, France.

ARTICLE INFO

Article history:

Received 26 March 2019

Accepted 4 April 2019

Keywords:

Breast cancer

Radiation therapy

Mastectomy

Immediate reconstruction

Implant

Guidelines

ABSTRACT

Immediate breast reconstruction (IBR) rates after mastectomy are increasing. Postmastectomy radiation therapy (PMRT) contouring guidelines for target volumes in the setting of IBR are lacking. Therefore, many patients who have had IBR receive PMRT to target volumes similar to conventional simulator-based whole breast irradiation. The aim of this paper is to describe delineation guidelines for PMRT after implant-based IBR based on a thorough understanding of the surgical procedures, disease stage, patterns of recurrence and radiation techniques. They are based on a consensus endorsed by a global multidisciplinary group of breast cancer experts.

© 2019 Elsevier B.V. All rights reserved. Radiotherapy and Oncology 137 (2019) 159–166

Breast cancer is the most common non-skin cancer in women worldwide. The vast majority of patients have non-metastatic disease at diagnosis [1]. The rates of mastectomy with an immediate breast reconstruction (IBR), mainly an implant/prosthesis-based

reconstruction (IBR-i), as a surgical treatment for early breast cancer patients are increasing [2,3].

Indications for postmastectomy radiation therapy (PMRT) are based on tumour-related characteristics and other prognostic risk factors. Lately, the number of patients receiving PMRT [4] has increased based on evidence that PMRT for pN1 breast cancer patients treated with mastectomy and axillary dissection reduces recurrences and breast cancer mortality [4–6]. Although some studies have suggested that PMRT in the setting of reconstruction

* Corresponding author at: Radiation Oncology Unit, Oncology Institute, Rambam Medical Center, Haifa, Israel.

E-mail address: o_person@rambam.health.gov.il (O. Kaidar-Person).

¹ Both authors contributed equally.

increases the relative rate of complications regardless of the type (implant or autologous) and the timing of reconstruction [7–9], fewer complications and better long-term cosmetic outcome have been reported when an autologous flap-based reconstruction was performed compared to IBR-i in combination with PMRT [7–10]. The IBR-i has ~2.64 times higher odds of complications (95% CI 1.77, 3.94, $p < 0.001$) than autologous-flap-based reconstruction. The rates of reconstruction failure in the setting of PMRT at two years was reported to be 18.7% amongst patients with IBR-i versus 1% in the autologous reconstruction group [10].

Radiation therapy (RT) in the setting of breast reconstruction is challenging. Surgical techniques for breast reconstruction continue to develop with the aim of improving cosmetic outcomes via pre or retro-pectoral placement of the implant, or the use of an autologous-flap, lipofilling or synthetic coverage materials in conjunction with the implant [11]. However, little is known about the oncological outcomes associated with these techniques, the impact of RT on cosmetic results, and factors underpinning these outcomes after breast reconstruction and PMRT [2,7,9,12,13]. In addition, most studies of breast reconstruction and PMRT did not specify the influence of radiation techniques and dose-fractionation schedules used or the long-term oncological outcomes including patterns of recurrence [12–15].

Current PMRT techniques used in the post-IBR setting are still often field-based rather than volume-based such that the target volume frequently includes the implant or reconstructed breast itself. The use of modern volume-based RT planning may reduce the dose to normal tissue and thereby treatment-related toxicity, without compromising target coverage [16].

Our multidisciplinary initiative aims to define delineation guidelines for the clinical target volume (CTV) for PMRT in the setting of IBR-i and autologous IBR (IBR-a). This manuscript focuses on the setting of IBR-i, presenting the consensus guideline aiming to limit the CTV to clinically relevant volumes and thereby the risks of RT-related complications.

Methods

In February 2016 the challenges of PMRT in the setting of IBR were discussed at the Assisi Think-Tank Meeting on breast cancer [17]. In addition, development of the DBCG RT Recon Trial (ClinicalTrials.gov NCT03730922), a randomised study of the Danish Breast Cancer Group (DBCG) for patients who require PMRT and plan to have IBR-i as a first step of a delayed-immediate breast reconstruction necessitated development of guidelines for target volume delineation. An international group of breast cancer experts (BVO, PP, OKP, LB, CC, IM) developed a delineation guideline including CTV definition for the DBCG trial, and evaluated its feasibility and dosimetric considerations using treatment planning CT scans of two patients who had an IBR-i [18].

In November 2017 a broader international multidisciplinary group of breast cancer experts including breast surgeons, plastic surgeons, radiation oncologists, and clinical oncologists (authors list) was invited to participate in the consensus guidelines development via the following steps:

- (1) Between January and March 2017 the current practices for IBR-PMRT of the expert group were assessed via a multiple-choice web-questionnaire of 6 questions (Table 1).
- (2) The expert group participated in a European Society of Radiation & Oncology (ESTRO)'s Fellowship in Anatomic delineation and CONtouring (FALCON) platform-based [19] CTV contouring exercise using four representative cases which comprised two IBR-i cases and two-IBR-a cases. The writers of the DBCG RT Recon Trial guidelines visually compared and

Table 1
Prework web-questionnaire.

Question	Answers (# of participants)
In your daily practice, in case of IBR irradiation do you delineate target volume of chest wall/reconstructed breast?	a. "yes", in most cases. Target volumes are used for treatment set-up. (18) b. "yes", in most cases, after virtual simulation to enable dose homogenisation. (2) c. "no", in most cases we irradiate the volume of the whole reconstruction breast (similar volumes like virtually simulated RT for breast in place). (8)
In the affirmative, do you delineate the clinical target volume according to the surgical procedure?	a. "yes", in most cases. (15) b. "no", the target volume is in general very similar. (9) c. "no", the target volume is similar like for the breast in place. (1)
In the affirmative, in which case do you find it easier to delineate the clinical target volume?	a. In cases of IBR-i. (17) b. In both IBR-i and IBR-a. (6) c. None. (3)
What would be helpful to define the clinical target volume in cases of IBR?	a. Detailed surgical and pathological report. (5) b. Delineating with the assistance of a breast surgeon. (1) c. Extensive marking of scars and palpable/visible surgical effects. (0) d. At least 2 of the above. (12) e. a + b + c (8) f. The clinical target volume should be the IBR (similar to virtual RT for breast in place) irrespective of the type of surgery performed. (3)
Can volume delineation guidelines for IBR according to the surgical procedure be applied in the clinical practice?	a. "yes". (23) b. "no", until data from clinical trials is available. (4) c. "no", surgical procedures change significantly which might compromise oncological outcomes. (1)
How many PMRT IBR cases you treat a year?	a. <10 (7) b. 10–20 (7) c. >20 (14)

RT – Radiation therapy; PMRT – Postmastectomy radiation therapy; IBR-immmediate breast reconstruction; IBR-i – implant-based; IBR-a – autologous tissue based.

discussed the CTVs contoured separately for the group involved in development of the DBCG delineation guidelines and the group of experts who were not involved. This was also done separately for the breast- and plastic surgeons and oncologists. Email correspondences amongst the participants regarding the challenges in contouring the CTVs were reviewed and discussed.

- (3) The project was presented by PP at the 11th European Breast Cancer Conference (EBCC11) in March 2018, and a panel discussion was conducted about potential factors associated with cosmetic outcomes in the setting of IBR and PMRT. This panel included three more representatives from our breast cancer expert team (FM, MJC, OKP).
- (4) Sixteen expert team members met in a closed session at ESTRO 37 in April 2018 to discuss outcomes of the survey and delineation exercise; challenges of CTV delineation for IBR-i versus IBR-a; additional data required to complete the consensus guidelines especially for IBR-a; modification of the guidelines based on surgical data, disease stage, site of recurrence; and current practices.

- (5) An open panel discussion chaired by BVO was held at ESTRO 37 in April 2018. The project was presented by PP [20] and OKP [21]. Input from the audience was taken into consideration in the consensus guidelines development.
- (6) At all times, the expert group members communicated via email to resolve outstanding issues in guidelines development. The core group (BVO, PP, OKP) conducted teleconferences and face-to-face meetings to finalise the guidelines.
- (7) The draft manuscript was written by the core group (BVO, PP, OKP), and reviewed and approved by all authors. The other expert group members are acknowledged in the manuscript.

Results

Group pre-work based on web-questionnaire

According to the results of web-questionnaire (Table 1), most participants agreed that target volume delineation guidelines for IBR according to the surgical procedure can be applied in clinical practice once they are made available.

Results of delineation exercise

The visual comparison of the CTV contours between the different groups of contributors to the guideline is illustrated in Fig. 1. A high consistency was observed amongst the writers of the DBCG RT Recon Trial, half of the other radiation oncologists and one surgeon. Whilst the other surgeon contoured a much smaller CTV, the other half of the radiation oncologists included the entire chest wall with the implant, similar to a conventional simulator-based treatment set up.

Recommendations on target volume delineation for chest wall

A sound understanding of the breast's anatomy, regional lymphatics drainage patterns, disease stage, and procedures of breast surgery and IBR is essential to guide delineation of the CTV_{p_chest wall} (i.e., *p* – primary). Detailed surgical and pathological reports are required. We recommend marking of scars and palpable/visible anatomical and surgical effects such as the borders of the surgical resection of subcutaneous, breast and fatty tissue.

Although the skin is not part of the CTV, except in patients with a T4b, T4c and T4d breast cancer, the subcutaneous lymphatic plexus clearly is. During a total mastectomy the skin is pulled together and sutured, thereby reducing the size of the CTV_{p_chest wall} compared to a CTV_{p_breast}. The surface-reducing effect of mastectomy as described above is not the case when skin-sparing (with removal of nipple-areolar complex) or nipple-sparing (with preservation of skin and nipple-areolar complex)

mastectomy is performed. These surgical approaches have gained popularity as initial reports have not shown a higher local recurrence rate than patients treated with skin-ablating mastectomy [22]. However, as more skin is preserved, it is likely that there will be more residual draining lymphatics and mammary glandular tissue [23], potentially resulting in an increase in local recurrence risk [23–25]. Moreover, uncertainty in defining the residual glandular tissue remains due to the limited data available [24,26,27]. The location of the residual glandular tissue varies in individual patients and depending on surgical procedure performed (with/without skin or nipple sparing). In most patients, it is found laterally in the “axillary-tail” and in up to 22% of cases in the upper inner quadrant [23]. We strongly recommend that the borders of residual skin be determined in conjunction with the surgeon and marked before planning CT scanning. The CT scans should also be reviewed for residual tissue that is not evident on physical examination.

Understanding the mammary lymphatic drainage pattern

The lymphatics from the mammary region drain via the dermal plexus located within the subcutaneous tissues (Fig. 2). The glandular tissue over the dorsal fascia of the breast is not connected to the major pectoral muscle, and hence, in the absence of tumour invasion the muscle is not part of the CTV_{p_chest wall}. About three quarters of the lymphatics drains to the axillary nodes. The lymphatics may also drain into a connection along the borders of the glandular tissue and then around the edge of the major pectoral muscle into the interpectoral (Rotter's) nodes (Fig. 2) or through or between the pectoral muscles directly to the apical axillary nodes. Lymphatics may finally also drain alongside the penetrating blood vessels through the medial side of the major pectoral muscle into the internal mammary nodes. Thus, the deep lymphatic plexus (Fig. 2, level 2–4) is part of the target volume in patients with more advanced breast cancer who should also be considered for internal mammary lymph node irradiation [28–30]. Target volumes for elective nodal irradiation should be contoured according to the ESTRO guidelines [31,32].

Understanding the surgical procedure of IBR-i

The mastectomy procedure may vary according to oncological and aesthetic requirements. In general, the mammary gland is dissected from the skin envelope along the subcutaneous (Scarpa's fascia) plane. The nipple areolar complex may or may not be preserved (see below). The gland is dissected off the pectoral muscle in the plane between the retro-mammary and pre-pectoral fascia, preserving the fascia if oncologically appropriate.

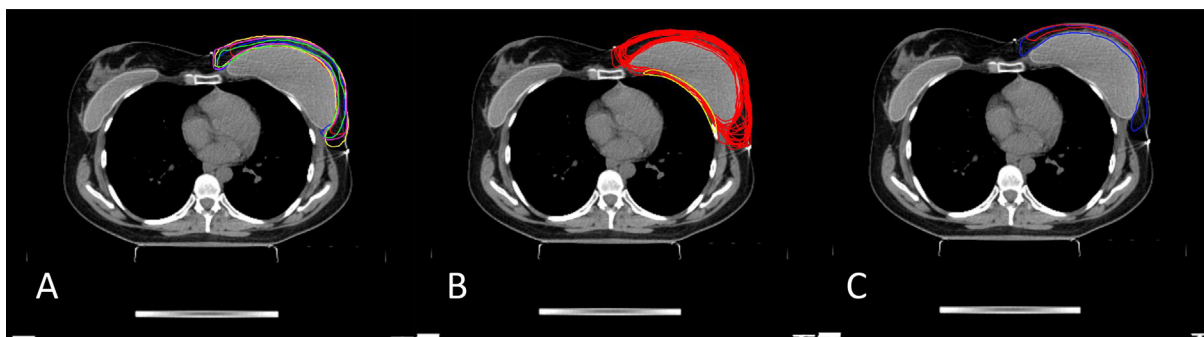
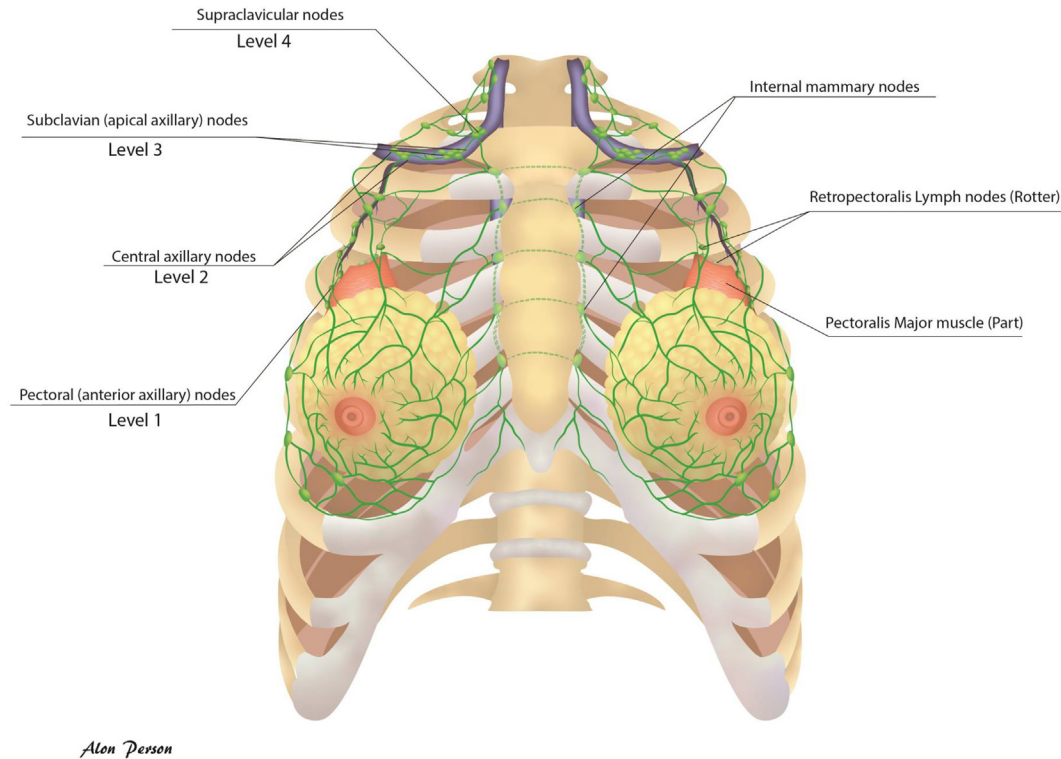


Fig. 1. CTV contouring of case with immediate breast reconstruction left using an implant. (A) by writers of guideline of DBCG RT Recon Trial ($n = 5$); (B) by other radiation oncologists ($n = 18$); (C) by breast cancer surgeons ($n = 2$).



Alon Persson

Fig. 2. Lymphatic draining pattern from the mammary region via the dermal plexus located within the subcutaneous tissues.

The implant (tissue expander or permanent implant) may be positioned *pre* or *post* to the major pectoral muscle:

- (1) *Posterior (dorsal)* to the major pectoral muscle (retro-pectoral position). Additional materials e.g. de-epithelialized dermal flap, synthetic mesh or a bio-mesh of animal or human tissues (acellular dermal matrix- ADM) are most often used to provide complete coverage of the implant caudally of the pectoral muscle and to achieve the preferred breast shape (Fig. 3A, B).
- (2) *Anterior (ventral)* to the major pectoral muscle (pre-pectoral) directly into the skin pocket. The implant is secured in position with a mesh covering the largest part of the superficial surface of the implant (Fig. 3C) [33,34].

After mastectomy, the CTV_p_chest wall includes the residual subcutaneous glandular tissue and the subcutaneous lymphatics. The major pectoral muscle serves as the anatomical *dorsal* border for mastectomy. The muscle is typically described in anatomy textbooks as a thick fan-shaped muscle, originating from the medial half of the clavicle and *ventral* surface of the sternum as well as the cartilage of the 6th or 7th rib, and inserting into the bicipital groove and deltoid tuberosity of the humerus. Therefore, former CTV_p_chest wall usually includes the levels from 2nd to 6th rib in *craniocaudal* direction. However, according to the ESTRO guideline [31,32], observing mastectomy procedures for the purpose of developing the current guidelines and evaluating RT-planning CT-scans, anatomical aspects such as size (extent and thickness) of the major pectoral muscle and position of the breast varies amongst women, dependent on age, body mass index, patient's fitness, etc. Therefore, in general most of the breast glandular tissue is positioned ventral to the major pectoral muscle, whilst a smaller more lateral part of glandular tissue is located ventral to the anterior serratus muscle and more caudally ventral to the ribs and intercostal muscles and in some patients, up to the ventral part

of the external oblique abdominal muscle (Fig. 4A,B). Consequently, per ESTRO recommendation for CTV_p_chest wall delineation, the *cranio-caudal borders* should be defined by careful clinical examination of the patient with positioning of skin markers for the planning-CT (e.g., scars) and taking into account the position of the contralateral breast. It is not advisable to use the latter as a mere mirror because during mastectomy, both parts of the CTV are approximated, thereby reducing the surface of the target volume compared to the intact breast [31,32]. The *medial* and *lateral* borders should be per ESTRO recommendations for chest wall delineation [31,32].

Importantly, approximately 5–10% of the glandular tissue is retained after conventional total mastectomy [23]. It is essential to include residual glandular tissue within the CTV_p_chest wall.

CTV_p_chest wall after IBR general

Our recommendations for the CTV_p_chest wall are based on the observation that most of the local recurrences after mastectomy occur at the level of the skin and subcutaneous tissue (range, 72–100%), where most of the residual glandular tissues and draining lymphatics are found [35,36]. The second most common site of recurrence is within the pectoral muscle, especially near the primary tumour site (0–28%) [35,36]. In general, the CTV_p_chest wall is positioned *ventral* (anterior) to the major pectoral muscle. In case of muscle invasion, local inclusion of that part of the pectoral muscle is advised, and in case of rib cage invasion the ribs/intercostal muscles should also be focally included in the CTV [32]. As IBR is generally not advised in these patients, the *dorsal* (posterior) border of the CTV in most cases will be on the *ventral* side of the major pectoral muscle or the ribs and intercostal muscles where no pectoral muscle was present before surgery [32]. In the case of a retro-pectoral implant, the surgeon generally detaches the caudal and medial insertion of the major pectoral muscle. If

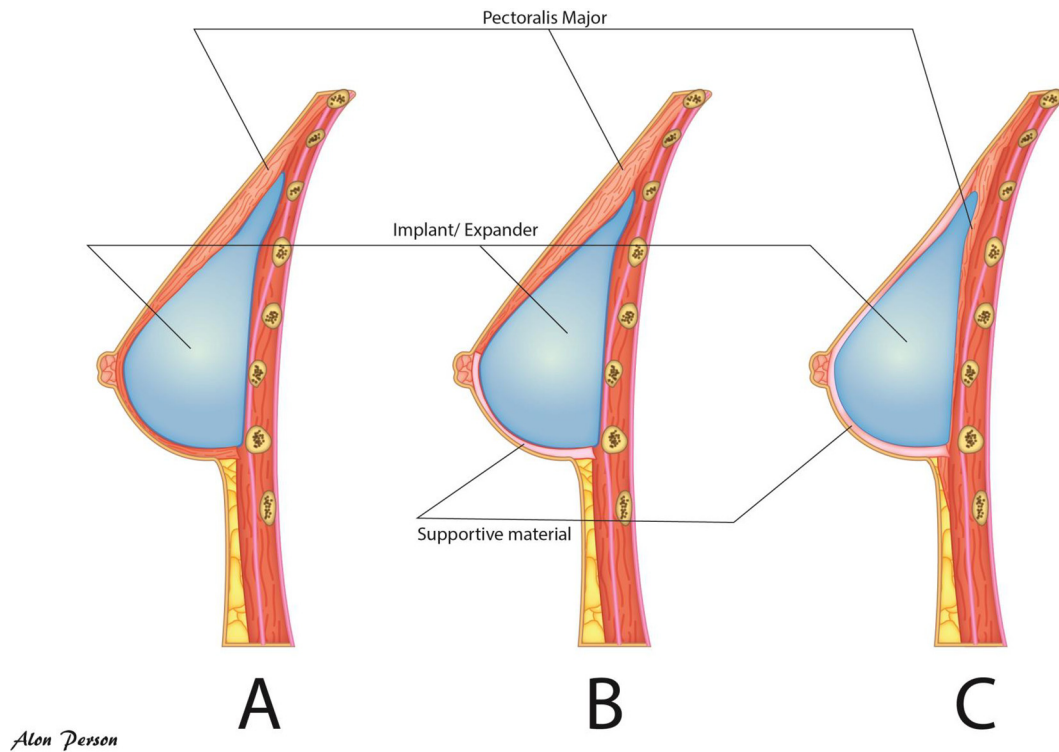


Fig. 3. Implant positioning. (A) retropectoral with full coverage by the pectoral muscle; (B) retro-pectoral with partial coverage by the pectoral muscle and supportive material in the lower part; (C) pre-pectoral with full coverage by supportive material.

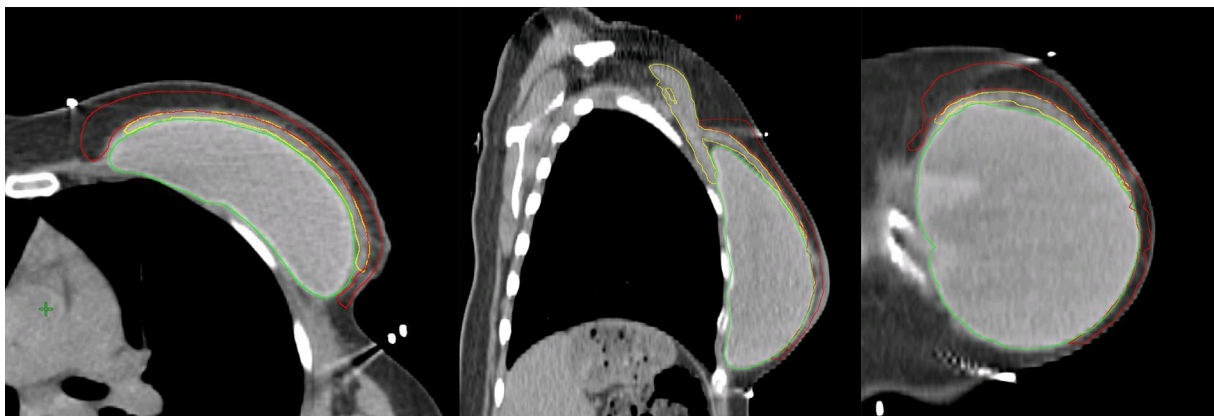


Fig. 4a. CTVp_chestwall with only a ventral part (red) in cases for whom only the subcutaneous lymphatic plexus should be irradiated. Pectoral muscles (yellow) and implant (green).

thereby the original position of the pectoral muscle cannot be clearly identified on the planning CT scan, the *dorsal* CTV border may be extended locally over the *ventral* side of the ribs [36,37]. It is therefore strongly advised that the surgeon places clips to assist in the location of the primary tumour site and in the case of a retro-pectoral implant also of the pre-surgical insertion of the major pectoral muscle on the ribs. Delineation should preferably be undertaken in conjunction with the surgeon to individualise the CTVp_chest wall according to the primary tumour site and degree of tumour extension.

CTVp_chest wall after IBR using retro-pectoral implant (Fig. 3A, B)

If the dorsal fascia of the breast is not involved by cancer, the CTVp_chest wall for PMRT does not include the deep lymphatic plexus and therefore only includes the rim of tissue ventral to the

major pectoral muscle and the implant, except at the medial, lateral and caudal borders where it may extend to the *ventral* side of the chest wall where it is not covered by the pre-surgical extension of the major pectoral muscle. Thus, the implant can be largely excluded from the CTVp_chest wall, whilst the parts of the chest wall surrounding the pectoral muscle around which the lymphatics flow should still be included (Fig. 4A, B). As the pectoral muscle overlying the implant is very thin in some women, the muscle would inevitably be included at least partially in the CTV, meaning that the dorsal margin of the CTV would be at the ventral side of the implant.

For patients with adverse factors and/or where the tumour was localised in areas within the breast close to the dorsal fascia (tumour on ink at the dorsal fascia) that was not covered by the major pectoral muscle (mainly caudally located tumours that are often located adjacent to the intercostal muscles and ribs), only separated by the dorsal breast fascia, we recommend to delineate

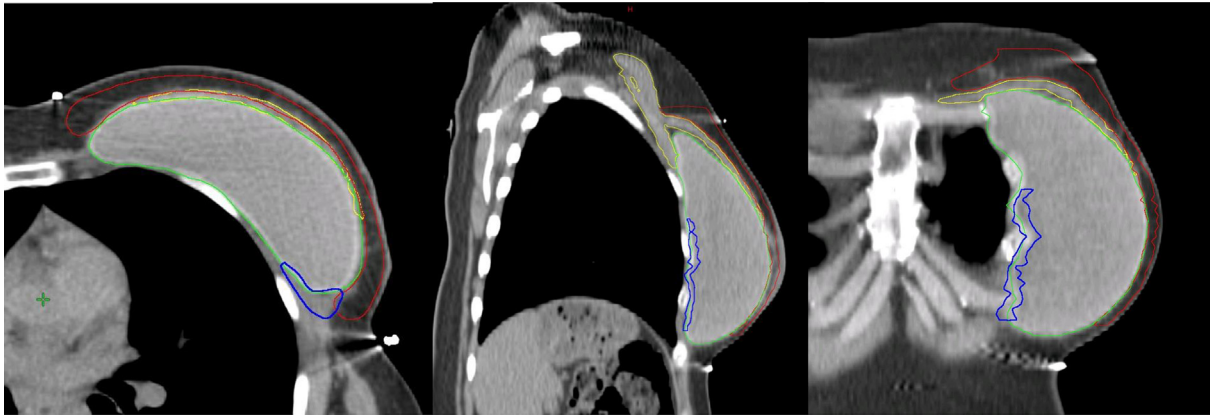


Fig. 4b. CTVp_chestwall with a ventral (red) and dorsal (blue) part in cases for whom the subcutaneous lymphatic plexus should be irradiated as well as the part of the chest wall that was initially not covered by the pectoral muscles (yellow). Retropectoral implant (green).

the tissue between the chest wall and the implant caudal from the pre-surgical position of the major pectoral muscle (ideally marked by surgical clips), which can be done as a separate dorsal CTV (Table 2; Fig. 4B).

CTVp_chest wall after IBR with pre-pectoral implant

After IBR-i using a pre-pectoral positioned implant, the CTVp_chest wall is composed of 2 parts as the pre-pectoral volume is divided into 2 parts by the implant (Fig. 3C):

- (1) the ventral part between the skin and the implant, containing the subcutaneous lymphatic plexus and eventual residual glandular tissue (Fig. 4C, red contour);
- (2) the dorsal part between the implant and the pectoral muscle/chest wall, containing eventual residual glandular tissue (Fig. 4C, blue contour): only to be included in case of the presence of adverse tumour factors (Table 2).

Volumes to be delineated: summary

The implant and the contralateral breast should be delineated using a planning-CT (Table 3). The transplanted tissues (skin; fat; muscle) and synthetic materials (implant, tissue expander, ADM) are not part of the CTV. They could be contoured as organs at risk (OAR), without the aim to compromising the CTVp_chest wall coverage. Other OARs that should be delineated for treatment planning purposes include heart, lungs, liver, thyroid and, in case of axillary lymph node irradiation with a regional boost, the brachial plexus.

Discussion

Consensus-based guidelines on radiation target volume definition in patients with breast cancer treated with mastectomy and IBR are lacking. Most publications reporting on PMRT after immediate or other breast reconstruction do not provide sufficient

Table 2

Indications for including a volume posterior to the implant in the CTVp_chestwall.

Partial inclusion in retro-pectoral implant positioning: in case of the presence of adverse factors and/or if the tumour was localised in areas within the breast close to the dorsal fascia that was not covered by the initial position of the major pectoral muscle: separate volume (blue volume in Fig. 4B)

Complete inclusion in pre-pectoral implant positioning: in case of the presence of adverse factors (blue in Fig. 4C)

Adverse prognostic tumour characteristics include:

- Large primary breast cancer (pT3) treated by mastectomy and IBR-i
- Locally advanced breast cancer (LABC) with non-pathological complete response to primary systemic therapy
- Invasion of the major pectoral muscle and/or the chest wall

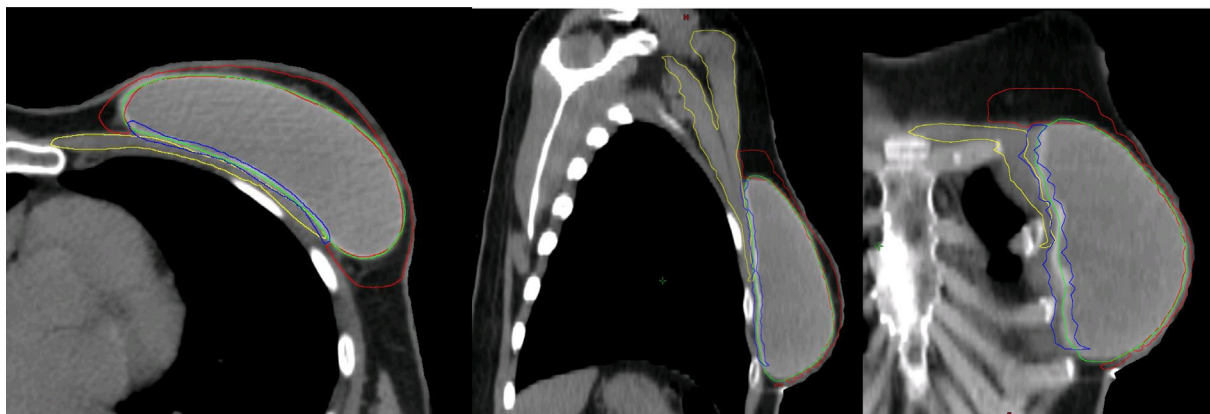


Fig. 4c. CTVp_chestwall with a ventral (red) and dorsal (blue) part in cases with a prepectoral implant (green). Pectoral muscles (yellow).

Table 3

ESTRO delineation guidelines for the CTV in case of implant-based immediate breast reconstruction*. The ventral or superficial part of the CTVp_chestwall includes the space between the skin and the superficial sides of the pectoral muscles and the implant when/where not covered by muscle. The dorsal or deep part of the CTVp_chestwall is the virtual space between the dorsal side of the implant and the pectoral muscles or ribs and intercostal muscles where no muscle is present. Whilst the ventral part is always part of the CTV, the dorsal part is only included depending on anatomical and tumour-related risk factors that are listed in Table 2.

Border per region	CTV Retro-pectoral implant	CTV Pre-pectoral implant
Cranial	Guided by palpable/visible signs, planning CT; if appropriate guided by the contralateral breast; maximally up to the caudal edge of the sterno-clavicular joint	Guided by palpable/visible signs, planning CT; if appropriate guided by the contralateral breast; maximally up to the caudal edge of the sterno-clavicular joint
Caudal	Guided by palpable/visible signs; if appropriate guided by the contralateral breast	Guided by palpable/visible signs; if appropriate guided by the contralateral breast
Ventral	1. Ventral part: if possible, up to 3–5 mm under the skin surface; 2. Dorsal part caudal from original insertion of pectoral muscle: the dorsal side of the implant.	1. Ventral part: if possible up to 3–5 mm under the skin surface; 2. Dorsal part: the dorsal side of the implant.
Dorsal	1. Ventral part: major pectoral muscle or implant where no muscle; 2. Dorsal part caudal from original insertion of pectoral muscle: ribs and intercostal muscles. **consider including the superficial part of the pectoral muscle if it is thin or in case of local invasion.	1. Ventral part: ventral side of the implant. 2. Dorsal part: ventral side of the pectoral muscles or ribs and intercostal muscles where no muscle is present. **consider including the superficial part of the pectoral muscle in case of local invasion.
Medial	Guided by palpable/visible signs; if appropriate guided by the contralateral breast. Lateral to the medial perforating mammary vessels.	Guided by palpable/visible signs; if appropriate guided by the contralateral breast. Lateral to the medial perforating mammary vessels.
Lateral	Guided by palpable/visible signs; if appropriate guided by the contralateral breast. Usually ventral to the mid-axillary line (important, location of most residual glandular tissue). Ventral to the lateral thoracic artery.	Guided by palpable/visible signs; if appropriate guided by the contralateral breast. Usually ventral to the mid-axillary line (important, location of most residual glandular tissue). Ventral to the lateral thoracic artery.

*Some of the CTV borders are as previously published in ESTRO guidelines on target volume delineation for elective radiation therapy of early stage breast cancer [21].

details on target volume delineation and RT planning. The current paper provides a detailed delineation guideline for PMRT after IBR-i endorsed by a global multidisciplinary group of breast cancer experts.

It is recommended that the guidelines be considered in the context of complete information about loco-regional disease staging (including staging pre and post primary systemic therapy if applicable); individual anatomical variations (e.g. chest wall thickness); location of potential residual glandular tissue in discussion with the surgical team; evaluation of the contralateral intact breast and the pectoral muscles on planning CT; and the surgical procedures.

Multidisciplinary collaboration is essential; breast surgeons are important partners in contouring the appropriate CTVp_chest wall. Moreover, patients who are planned to have a mastectomy and IBR-i should be pre-operatively evaluated by both the surgeons and radiation oncologists or alternatively, discussed at multidisciplinary tumour board meetings.

Selected patients with LABC may be considered for IBR. In these cases, the CTV, based on the general guidelines and discussions in a multidisciplinary team conference, should be if required carefully individually adapted per case, according to the high-risk areas for remaining subclinical tumour deposits. In any case that the tumour staging is unknown/unclear, we recommend to irradiate after IBR-i in a manner similar to conventional simulator-based RT approaches for preserved breast irradiation, thereby including the entire mastectomy site including the implant.

If the skin is not part of the target volume, the *ventral* limit is conventionally 5 mm deep to the skin surface to include the subcutaneous lymphatics of the breast. However, this may not be possible due to the surgical procedure and the stretching of the remaining skin over the implant resulting in a thin rim of skin envelop, making it impossible to crop the CTVp_chest wall to 5 mm below the skin surface. There is no high-level evidence to guide the use of bolus material to increase the skin dose in PMRT after IBR. In preparation of the DBCG RT Recon trial protocol, planning of two test cases using a tangential, forward planned field-in-field technique showed that there was 100% skin dose over most of the reconstructed breasts with 6 MV photons without a bolus, except medially and laterally corresponding to entry and exit of the beams. Due to the potentially superficial location of subcutaneous lymphatics, we do not recommend cropping of the CTVp_chest wall 5 mm from the skin surface but, depending on the software for dose calculation used, including the skin surface in the CTVp_chest wall without routinely using additional bolus to optimise inverse treatment plan calculations and DVH-evaluation of the dose distribution.

After a mastectomy with IBR, identification of the tumour bed is complex and challenging due to manipulation of the tissue during reconstruction. Therefore, we do not recommend the use of a “tumour bed” boost, unless the surgeon has placed clips to mark anticipated and subsequently confirmed involved resection margins that cannot be removed surgically.

The current guidelines are intended for target volume delineation after IBR-i. Development of target volume delineation guidelines after IBR-a is in progress and is more complicated due to the range of surgical procedures. This paper does not support one breast reconstruction procedure over the other.

Using volume-based RT, we aim to reduce potential complications by tailoring the target volume to tissues at risk for recurrence. It is necessary that patients treated according to the current guidelines be carefully monitored in terms of long-term oncological safety, treatment toxicity and cosmetic outcome. Hence, we support initiatives of prospective databases, such as the INSPIRE prospective cohort study and the Mastectomy Reconstruction Outcome Consortium (MROC) [10] to evaluate patient outcomes after mastectomy and reconstruction. We also encourage centres to participate in clinical trials such as the DBCG RT Recon Trial or the Primary Radiotherapy And DIEP flAp Reconstruction Trial (PRADA) (NCT02771938) (<https://clinicaltrials.gov/ct2/show/NCT02771938>), and contribute data to the prospective cohort study coordinated by the authors of the current guidelines (NCT03730922).

Disclaimer

ESTRO cannot endorse all statements or opinions made on the guidelines. Regardless of the vast professional knowledge and scientific expertise in the field of radiation oncology that ESTRO possesses, the Society cannot inspect all information to determine the truthfulness, accuracy, reliability, completeness or relevancy thereof. Under no circumstances will ESTRO be held liable for any decision taken or acted upon as a result of reliance on the content of the guidelines.

The component information of the guidelines is not intended or implied to be a substitute for professional medical advice or medical care. The advice of a medical professional should always be sought prior to commencing any form of medical treatment. To this end, all component information contained within the guidelines is done so for solely educational and scientific purposes. ESTRO and all of its staff, agents and members disclaim any and all warranties and representations with regards to the information contained on the guidelines. This includes any implied warranties and conditions that may be derived from the aforementioned guidelines.

Acknowledgments

The authors would like to thank Liesbeth Boersma, Alice Ho, Claus Kamby, Fiona MacNeill, Sofia Rivera, Yvonne Zissiadis, Alon Person, and Miika Palmu for their support and assistance with this project.

The authors dedicate these guidelines to all breast cancer patients, past, present and future.

None of the authors has any conflict of interest regarding the publication of this manuscript.

Illustrations were done by Alon Person, via Adobe Illustrator cc 2019.

References

- Bray F, Ferlay J, Soerjomataram I, Siegel RL, Torre LA, Jemal A. Global cancer statistics 2018: GLOBOCAN estimates of incidence and mortality worldwide for 36 cancers in 185 countries. *CA Cancer J Clin* 2018.
- Agarwal S, Kidwell KM, Farberg A, Kozlow JH, Chung KC, Momoh AO. Immediate reconstruction of the radiated breast: recent trends contrary to traditional standards. *Ann Surg Oncol* 2015;22:2551–9.
- Kummerow KL, Du L, Penson DF, Shyr Y, Hooks MA. Nationwide trends in mastectomy for early-stage breast cancer. *JAMA Surg*. 2015;150:9–16.
- Frasier LL, Holden S, Holden T, Schumacher JR, Leverson G, Anderson B, et al. Temporal trends in postmastectomy radiation therapy and breast reconstruction associated with changes in national comprehensive cancer network guidelines. *JAMA Oncol* 2016;2:95–101.
- Ebctcg McGale P, Taylor C, Correa C, Cutter D, Duane F, et al. Effect of radiotherapy after mastectomy and axillary surgery on 10-year recurrence and 20-year breast cancer mortality: meta-analysis of individual patient data for 8135 women in 22 randomised trials. *Lancet* 2014;383:2127–35.
- Marks LB, Kaidar-Person O, Poortmans P. Regarding current recommendations for postmastectomy radiation therapy in patients with one to three positive axillary lymph nodes. *J Clin Oncol* 2017;35:1256–8.
- Momoh AO, Ahmed R, Kelley BP, Aliu O, Kidwell KM, Kozlow JH, et al. A systematic review of complications of implant-based breast reconstruction with prereconstruction and postreconstruction radiotherapy. *Ann Surg Oncol* 2014;21:118–24.
- Kelley BP, Ahmed R, Kidwell KM, Kozlow JH, Chung KC, Momoh AO. A systematic review of morbidity associated with autologous breast reconstruction before and after exposure to radiotherapy: are current practices ideal? *Ann Surg Oncol* 2014;21:1732–8.
- Jagsi R, Jiang J, Momoh AO, Alderman A, Giordano SH, Buchholz TA, et al. Complications after mastectomy and immediate breast reconstruction for breast cancer: a claims-based analysis. *Ann Surg* 2016;263:219–27.
- Jagsi R, Momoh AO, Qi J, Hamill JB, Billig J, Kim HM, et al. Impact of radiotherapy on complications and patient-reported outcomes after breast reconstruction. *J Natl Cancer Inst* 2018;110.
- Cook LJ, Kovacs T. Novel devices for implant-based breast reconstruction: is the use of meshes to support the lower pole justified in terms of benefits? A review of the evidence. *Ecanermedscience* 2018;12:796.
- Lohmander F, Lagergren J, Roy PG, Johansson H, Brandberg Y, Eriksen C, et al. Implant based breast reconstruction with acellular dermal matrix: safety data from an open-label, multicenter, randomized, controlled trial in the setting of breast cancer treatment. *Ann Surg* 2018.
- Krastev T, van Turnhout A, Vriens E, Smits L, van der Hulst R. Long-term follow-up of autologous fat transfer vs conventional breast reconstruction and association with cancer relapse in patients with breast cancer. *JAMA Surg* 2018.
- Poppe MM, Agarwal JP. Breast reconstruction with postmastectomy radiation: choices and tradeoffs. *J Clin. Oncol* 2017. JCO2017727388.
- Ho A, Cordeiro P, Disa J, Mehrara B, Wright J, Van Zee KJ, et al. Long-term outcomes in breast cancer patients undergoing immediate 2-stage expander/implant reconstruction and postmastectomy radiation. *Cancer* 2012;118:2552–9.
- Kaidar-Person O, Jones EL, Zagar TM. Team work: mastectomy, reconstruction, and radiation. *Plast Reconstr Surg Glob Open* 2017;5:e1385.
- Aristei C, Kaidar-Person O, Arenas M, Coles C, Offersen BV, Bourcier C, et al. The 2016 Assisi Think Tank Meeting on breast cancer: white paper. *Breast Cancer Res Treat* 2016;160:211–21.
- Nissen ESY HD, Andersen K, Boersma L, Boye K, Canter R, Coles C, Costa E, Daniel S, Ho S, Jensen I. E.L. PO-0918: Consensus on target volume delineation and treatment planning strategy for the DBCG RT Recon trial. *Radiother Oncol* 2018;127:S492–4.
- Eriksen JG, Salembier C, Rivera S, De Bari B, Berger D, Mantello G, et al. Four years with FALCON - an ESTRO educational project: achievements and perspectives. *Radiother Oncol* 2014;112:145–9.
- Poortmans P. SP-0017: Breast reconstruction: a past or present challenge for the radiation oncologist? *Radiother Oncol* 2018;127:s6.
- Kaidar-Person O. SP-0019: Brother and sister: guidelines for bringing breast reconstruction and radiation therapy together. *Radiother Oncol* 2018;127:S6–7.
- Carlson GW, Bostwick 3rd J, Styblo TM, Moore B, Bried JT, Murray DR, et al. Skin-sparing mastectomy. Oncologic and reconstructive considerations. *Ann Surg* 1997;225:570–5. discussion 5–8.
- Woitek R, Pfeiler G, Farr A, Kapetas P, Furtner J, Bernathova M, et al. MRI-based quantification of residual fibroglandular tissue of the breast after conservative mastectomies. *Eur J Radiol* 2018;104:1–7.
- Carlson GW, Styblo TM, Lyles RH, Bostwick J, Murray DR, Staley CA, et al. Local recurrence after skin-sparing mastectomy: tumor biology or surgical conservatism? *Ann Surg Oncol* 2003;10:108–12.
- Meretoja TJ, Rasia S, von Smitten KA, Asko-Seljavaara SL, Kuokkanen HO, Jahkola TA. Late results of skin-sparing mastectomy followed by immediate breast reconstruction. *Br J Surg* 2007;94:1220–5.
- Marta GN, Poortmans PM, Buchholz TA, Hijal T. Postoperative radiation therapy after nipple-sparing or skin-sparing mastectomy: a survey of European, North American, and South American Practices. *Breast J* 2017;23:26–33.
- Marta GN, Poortmans P, de Barros AC, Filassi JR, Freitas Junior R, Audisio RA, et al. Multidisciplinary international survey of post-operative radiation therapy practices after nipple-sparing or skin-sparing mastectomy. *Eur J Surg Oncol* 2017;43:2036–43.
- Poortmans PM, Collette S, Kirkove C, Van Limbergen E, Budach V, Struikmans H, et al. Internal mammary and medial supraclavicular irradiation in breast cancer. *N Engl J Med* 2015;373:317–27.
- Thorsen LB, Offersen BV, Dano H, Berg M, Jensen I, Pedersen AN, et al. DBCG-IMN: a population-based cohort study on the effect of internal mammary node irradiation in early node-positive breast cancer. *J Clin Oncol* 2016;34:314–20.
- Whelan TJ, Olivetto IA, Parulekar WR, Ackerman I, Chua BH, Nabid A, et al. Regional nodal irradiation in early-stage breast cancer. *N Engl J Med* 2015;373:307–16.
- Offersen BV, Boersma LJ, Kirkove C, Hol S, Aznar MC, Biete Sola A, et al. ESTRO consensus guideline on target volume delineation for elective radiation therapy of early stage breast cancer. *Radiother Oncol* 2015;114:3–10.
- Offersen BV, Boersma LJ, Kirkove C, Hol S, Aznar MC, Sola AB, et al. ESTRO consensus guideline on target volume delineation for elective radiation therapy of early stage breast cancer, version 1.1. *Radiother Oncol* 2016;118:205–8.
- Highton L, Johnson R, Kirwan C, Murphy J. Prepectoral implant-based breast reconstruction. *Plast Reconstr Surg Glob Open* 2017;5:e1488.
- Casella D, Di Taranto G, Marcasciano M, Sordi S, Kothari A, Kovacs T, et al. Evaluation of prepectoral implant placement and complete coverage with TLoop(R) Bra mesh for breast reconstruction: a prospective study on long-term and patient reported BREAST-Q outcomes. *Plast Reconstr Surg* 2018.
- Vargo JA, Beriwal S. RTOG chest wall contouring guidelines for post-mastectomy radiation therapy: is it evidence-based? *Int J Radiat Oncol Biol Phys* 2015;93:266–7.
- Vargo JA, Beriwal S. In reply to Chang et al.: Contouring guidelines for post-mastectomy radiotherapy a cry for international consensus. *Radiother Oncol* 2017;123:483–4.
- Chang JS, Byun HK, Kim JW, Kim KH, Lee J, Cho Y, et al. Three-dimensional analysis of patterns of locoregional recurrence after treatment in breast cancer patients: Validation of the ESTRO consensus guideline on target volume. *Radiother Oncol* 2017;122:24–9.